

# Pain-Relieving Continuous-Cleansing Dressing Allows Trauma Patients To Avoid Surgery

Linda LL Benskin, PhD, RN, SRN (Ghana), CWCN, DAPWCA: Independent Researcher/Educator for Village Health Workers and Ferris Mfg. Corp. Contact: LindaBenskin@utexas.edu

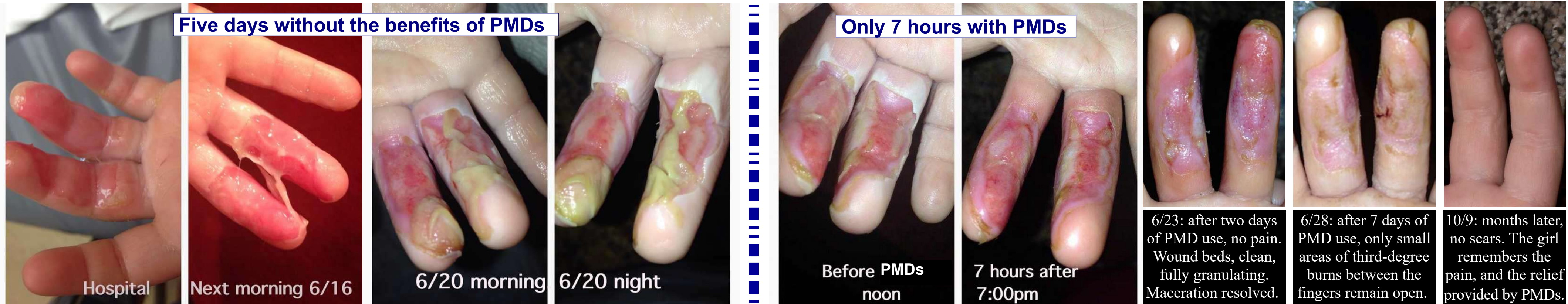
## INTRODUCTION

Patients with traumatic injuries tend to be anxious to return to their usual activities as quickly as possible, and are seldom eager to undergo surgery. The three patients described here were all referred to plastic surgeons for surgical debridement and grafting of their significant trauma wounds. These trauma patients needed immediate pain relief without incapacitating narcotics or clumsy dressings so that they could resume their active lives.

## METHODOLOGY

All three patients' wounds had been initially cleansed in the Emergency Department (ED), and the burn and elbow wounds had been managed with creams prior to PMD\* initiation. No other topical wound treatments were used with PMDs; none of wounds were even routinely rinsed. PMDs were simply removed and replaced by the patient or a family member when saturated. Prayer was also integral to the treatment.

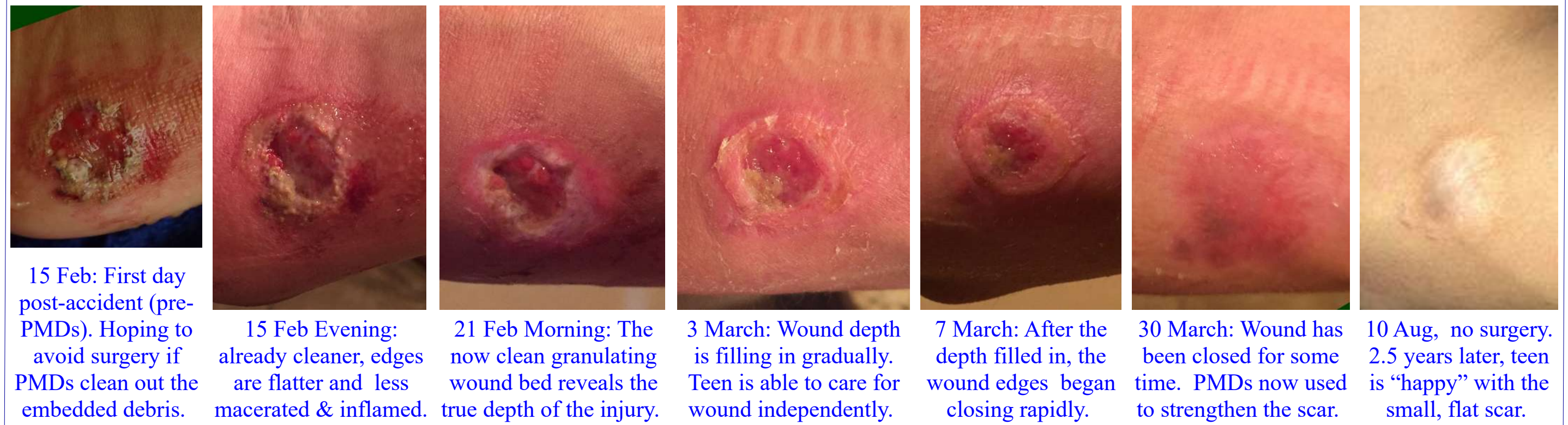**Patient 1:** A two-year-old girl reached into smoking glue from an industrial hot glue gun, resulting in extensive second- and third-degree burns to the middle and ring fingers of her dominant (L) hand. She was treated at the ED immediately and a burn center, who recommended grafts, the following day. The parents were instructed to cleanse the wounds daily, apply a cream thickly, wrap each finger individually with gauze strips, and secure the dressings with a self-adhesive wrap. Normal toddler activities resulted in soaked dressings that had to be replaced 3 or 4 times per day. Dressing changes were excruciating despite high doses of acetaminophen/codeine plus ibuprofen. Five days of persistent severe wound pain, copious thick yellow drainage, increasing maceration, and lack of healing led the mother to despair. At noon on post-injury day six, as an answer to prayer, PMDs arrived. The next day, the girl's mother wrote, "Yay for (PMDs). No pain, and she let me wrap it the way burn clinic wants it wrapped - gives full use to her fingers." The maceration resolved completely in only 7 hours, when the PMDs were changed because they have gotten soiled during play. After only two days of PMD use, all wound beds were clean, fully granulating, and superficial. The toddler played normally without requiring pain medications at all. No cleansing or even rinsing was needed at dressing changes. Complete closure took about 7 more days. PMDs were continued for a few weeks to strengthen the scar.



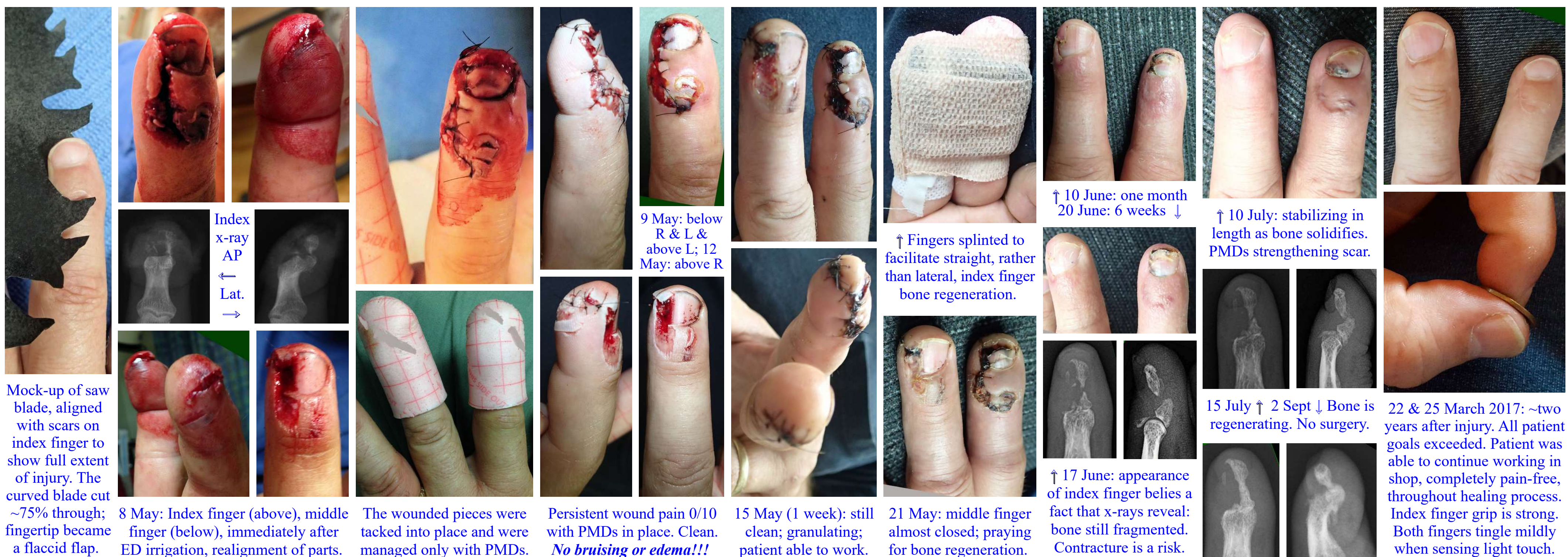## DISCUSSION

Polymeric membrane dressings\* (PMDs), originally designed to decrease pediatric burn patients' pain, were the ideal dressing choice for all three patients. PMDs decrease wound pain through four mechanisms: they are occlusive, they are nonadherent, they contain a continuous cleansing system so powerful that it eliminates the need for routine wound rinsing at dressing changes, and they decrease pain and inflammation directly by subduing and focusing the nociceptor response. Limiting inflammation can also decrease and strengthen scar, decrease edema, and improve lymphatic return, increasing circulation. Over 100 independent clinicians have found that PMDs speed healing when compared with other modern wound dressings.<sup>2</sup> The multiple components of PMDs work together with the body to soothe and add moisture to dry areas of the wound while removing excess moisture to resolve maceration. PMDs met every identified wound need.

**Patient 2:** A skateboard accident left a 14-year-old boy with a full-thickness 2.5 cm diameter left medial epicondyle area wound with exposed capsule. The ED physician stated that wound closure would take at least 6 weeks. He prescribed oral antibiotics, ibuprofen, and a cream and referred the teen to a plastic surgeon for debridement of the embedded dirt he was unable to remove with irrigation. The mother consulted a wound specialist nurse, who recommended allowing PMDs to atraumatically pull the debris from the wound bed. PMDs would also decrease the wound pain and edema, allow the boy to resume his activities more quickly, and support rapid healing. Using only PMDs, the teen's wound closed in less than 6 weeks, and he is happy with the final scar.



**Patient 3:** A middle-aged man who was startled in his workshop flinched, passing his first two fingers through the still-spinning table saw blade. He immediately applied pressure, rinsed the wounds, and applied PMDs designed for fingers and toes. The distal phalanx of the L index finger was shattered by the cut, which began at the medial tip of the finger and ended at the lateral base of the distal joint. The remaining soft tissue of the tip segment remained connected to the finger by only a small amount of soft tissue. A 0.3 cm soft-tissue kerf from the tip to the distal joint of the L middle finger was also removed by the saw blade. The ED physician irrigated the wounds again and, after consulting with a radiologist, determined that reconstructive surgery should be delayed until the inevitable swelling had run its course. However, this swelling never occurred, and when the hand surgeon examined the fingers the following week, he stated that he was very impressed. The x-rays from the ED had prepared him for a very different clinical presentation than what he saw now. The hand surgeon decided to leave in the "temporary" ED sutures tacking the parts together and allow the PMDs to promote the healing they could, delaying surgery. Later, it became clear that no surgery would be needed.



## OBJECTIVES

1. Recognize that superior healing can alleviate the need for surgical procedures such as grafting and reconstruction.
2. Observe how the continuous wound cleansing system built into PMDs can eliminate the need for surgical debridement.
3. Witness the four ways in which PMDs relieve wound pain.

## RESULTS

Analgesic use immediately decreased for all three patients when PMDs were initiated. The wounds closed more quickly than physicians expected, without the anticipated surgical debridement, grafting, and reconstruction procedures, and with dramatically decreased pain and inconvenience. The toddler has no evidence of her injury at all. The teen's elbow scar is quite acceptable to him. Amazingly, almost all of the man's finger length and function was restored, even in the case of the almost severed index finger.

## CONCLUSIONS

Each of these three patients used PMDs to manage their trauma wounds before their surgical appointments, and continued using the dressings until they had achieved a strong scar. In all three patients, the PMDs not only controlled pain and inflammation, they also did such a thorough job of cleaning the wounds and promoting healing that surgical intervention was not required. PMDs dramatically increased patient satisfaction with care.

## REFERENCES

1. Davies, S. L., & White, R. J. (2011). Defining a holistic pain-relieving approach to wound care via a drug free polymeric membrane dressing. *Journal of Wound Care*, 20(5), 250, 252, 254
2. Benskin, L. L. (2016). Polymeric Membrane Dressings for topical wound management of patients with infected wounds in a challenging environment: A protocol with 3 case examples. *Ostomy Wound Management*, 62(6), 42-62. [http://www.polymem.com/articles/Benskin-PMD-OWM\\_June2016.pdf](http://www.polymem.com/articles/Benskin-PMD-OWM_June2016.pdf)
3. Weissman, O., Hundeshagen, G., Harats, M., Farber, N., Millet, E., Winkler, E., ... Haik, J. (2013). Custom-fit polymeric membrane dressing masks in the treatment of second degree facial burns. *Burns*, 39(6), 1316-1320. <https://doi.org/10.1016/j.burns.2013.03.005>
4. Kim, Y. J., Lee, S. W., Hong, S. H., Lee, H. K., & Kim, E. K. (1999). The Effects of PolyMem(R) on the Wound Healing. *Journal of the Korean Society of Plastic and Reconstructive Surgery*, 26(6), 1165-1172.
5. Benskin, L. (2009). Excellent healing of pediatric wounds using polymeric membrane dressings... 41st Annual Wound, Ostomy and Continence Nurses Annual Conference, St. Louis, Missouri, June 6-10, 2009. *Journal of Wound, Ostomy & Continence Nursing*, 36(3S), S14-S14.
6. Scott, A. (2014). Polymeric membrane dressings for radiotherapy-induced skin damage. *British Journal of Nursing (Mark Allen Publishing)*, 23(10), S24, S26-31. <http://doi.org/10.12968/bjon.2014.23.Sup10.S24>

\*PolyMem® Dressings, PolyMem WIC® Silver®, PolyMem Cloth Island Dressings, and PolyMem Finger/Toe® Dressings, collectively referred to generically as "polymeric membrane dressings" or PMDs, are made by Ferris Mfg. Corp. in Fort Worth Texas, USA. The author (who performed the clinical work depicted here as a volunteer, and who designed this poster) is an employee of Ferris Mfg. Corp.