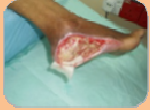

# Utilisation of Multifunctional Dressing on Stagnate, Draining Neuropathic Wound Using Polymeric Membrane Silver Dressing\*

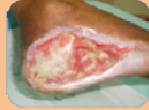DR Harikrishna K.Ragavan Nair (MD,FMSWCP) Hospital Kuala Lumpur, Malaysia.  
SR. Mah Yoke Har (SRN.DRM) Hospital Kuala Lumpur, Malaysia.

## ABSTRACT:

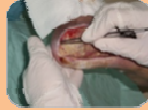Healing chronic neuropathic wounds requires a concerted multidisciplinary team effort. Strict adherence to infection control principles, regular wound bed preparation and observance to the TIME principles leads to healing.<sup>1</sup> The KL Foot Clinic is not concerned with only healing as an outcome but also educating and empowering the patient as well as the family members to promote long term functionally and to remain as contributing members of the community.



▲ 10/2/2011



▲ 14/2/2011



▲ 14/2/2011

## PATIENT HISTORY:

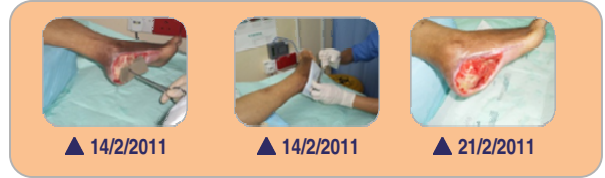Patient S is a 62 year old female diabetic whose injury occurred as a puncture from a staple. The damage was not discovered for at least 1 month following the initial injury due to the patients dense neuropathy. The wound was managed by different health care providers with various regimens prior to entry into the KL Hospital. The foot was debrided upon entry to the KL Hospital 10/2/2011 and cleaning of the wound cavity was performed. The lower limb was cleansed with a chlorhexidine sponge and the wound soaked for 10 minutes with prontosan. Multifunctional polymeric membrane silver was commenced 14/2/2011.

## AIM:

Multifunctional polymeric membrane silver dressing was selected on the 14/2/2011 for its ease and simplicity in dressing tunnels and cavities. It is important when using a dressing product in a cavity that the product does not leave any residue or particulate matter insitu. The silver in Multifunctional polymeric membrane silver dressing does not dump silver particles into the wound, studies have shown that silver dumping into the wound is cytotoxic and leads to delayed keratinocyte migration.<sup>3,4,5</sup> The Multifunctional polymeric membrane dressing with silver was chosen in the hope that it would reduce biofilm formation and enhance proliferation.

## METHOD:

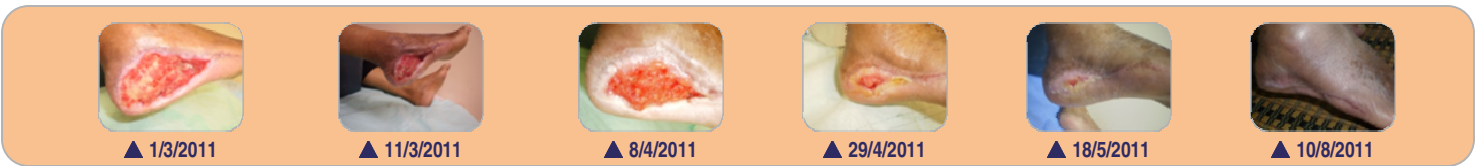A factor of concern was that the patient had to walk up 3 flights of stairs to her home. Offloading of pressure is an important component of managing the neuropathic foot.<sup>2</sup>. The nursing staff continued to debride callus at every dressing change. The multifunctional polymeric membrane was applied in the cavity and upon the wound and then the foot padded up to reduce pressure to the healing tissue on mobilization. The patient was supported well by family and was concordant with resting the limb and off loading the pressure. The wound continued to progress from the inflammatory phase into the proliferation phase without any regression in 2 months despite the patient being unable to afford a proper off- loading device. The nursing staff found that the Multifunctional polymeric membrane was a cost effective regimen because the wound did not regress and the products were easy to apply and remove.



▲ 14/2/2011

▲ 14/2/2011

▲ 21/2/2011



▲ 1/3/2011

▲ 11/3/2011

▲ 8/4/2011

▲ 29/4/2011

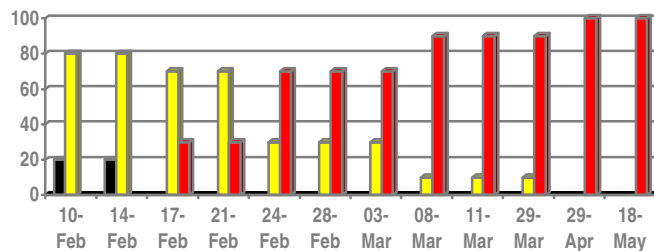
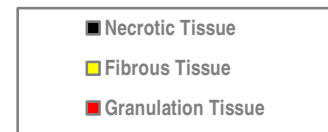
▲ 18/5/2011

▲ 10/8/2011

## WOUND PROGRESS:

The wound was reviewed in the clinic 13 times.

Date (2011)	Necrotic Tissue	Fibrous Tissue	Granulation Tissue
10-Feb	20	80	
14-Feb	20	80	
17-Feb		70	30
21-Feb		70	30
24-Feb		30	70
28-Feb		30	70
3-Mar		30	70
8-Mar		10	90
11-Mar		10	90
29-Mar		10	90
29-Apr			100
18-May			100



## CONCLUSION:

Polymeric membrane dressings have proven to be an effective factor in preventing biofilm development in an at risk neuropathic foot wound. It is a dressing that was also favourable to the staff and patient.

## INTRODUCTION:

It is estimated that 250 million people worldwide have diabetes, representing roughly 6% of the adult population (20-79 age group). The number is expected to reach some 380 million by 2025, representing 7.1% of the adult population. Diabetic foot problems are among the most serious and costly complications of diabetes. Statistics suggest that every 30 seconds a leg is amputated due to diabetic complications.<sup>1,2</sup>

Diabetic foot lesions are one of the most problematic wounds to manage in the community in Malaysia. Malaysia has a population of 28 million and 14.9% are diabetic according to the National Health Morbidity Study III in 2006. The National Diabetic Foot Registry has recorded amputation rates of up to 12%. A large number of diabetic foot patients who present at the hospitals are in the lower socio-economic groups and have limited education, often having only completed primary education, with some going onto secondary school.

Often patients with diabetic foot wounds have been managed in the community by alternate health practitioners. A wide variety of dressings have often been applied prior to admission to the KL clinic. Managing complex neuropathic foot wounds requires multi-disciplinary collaboration. Surgery is required as soon as the patient is stable to remove all devitalized tissue and drain sepsis. The patient and family are then encouraged to participate in the management program.

## Bibliography

- EWMA Position Document Wound Bed Preparation.
- International consensus and practical guidelines on the management and the prevention of the diabetic foot. International Working Group on the Diabetic Foot. Apelqvist J, Bakker K, van Houtum WH, Nabuurs-Franssen MH, Schaper NC
- A comparative study of the cytotoxicity of silver-based dressings in monolayer cell, tissue explant, and animal models. Burd A et al.
- Accumulation of Silver and Delayed Re-epithelialization in Normal Human skin: An ex-vivo Study of Different Silver Dressings. Fredriksson C. et al.
- Cytotoxicity testing of burn wound dressings, ointments and creams: A method using polycarbonate cell structure inserts on a cell culture system. Margit Kempf, Roy Kimble, Leila Cuttle.

\* PolyMem ® wound dressings. Manufactured by Ferris Mfg Corp, Burr Ridge, IL 60527 USA.